

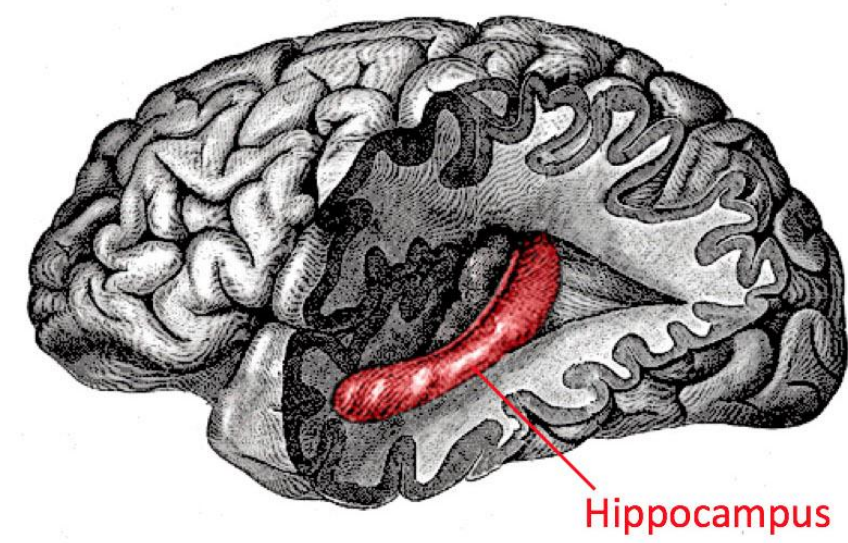
A Systematic Review of Hippocampal Volumetric Changes Post-ECT in Patients with MDD

Jasmine Haraburda, BS^{1,2}; Nasrallah, Henry, MD².

University of Cincinnati College of Medicine¹; Department of Psychiatry and Behavioral Neuroscience, University of Cincinnati College of Medicine².

Introduction

- Major depressive disorder (MDD) has a lifetime prevalence of 5-17%¹
- Electroconvulsive therapy (ECT) + antidepressants → improved clinical results for MDD compared to pharmacotherapy alone² (safe and effective, but stigmatized)
- ECT uses electrical currents to induce seizures without epilepsy
- Mechanism of ECT not fully understood
 - Hypothesized that ECT enhances neuroplasticity by stimulating neurogenesis → ECT-induced increases in N-acetyl aspartate (NAA), a marker of neuronal density and viability³
- Hippocampus plays a key role in MDD
 - Low hippocampal volume has been seen in MDD patients⁴
- Well established: ECT for MDD is efficacious & linked to increases in hippocampal gray matter volume (GMV)
- Remains unclear if it is post-ECT increases in hippocampal GMV that are driving symptomatic improvement



Study Objectives

Goals of this review:

- To summarize the impact of ECT on the hippocampus (as measured by structural MRI) in patients with major depressive disorder
- To elucidate if there is an association between hippocampal changes and improved clinical outcomes in MDD following ECT

Methods

A comprehensive literature search was conducted to identify relevant papers in August 2023 using the electronic database PubMed. This search included articles published in English within the last 10 years (from 2013 to 2023).

The following keywords were used: "hippocampus", "hippocampal", "ECT", "electroconvulsive therapy", "depression", "major depressive disorder", "MDD", "MRI".

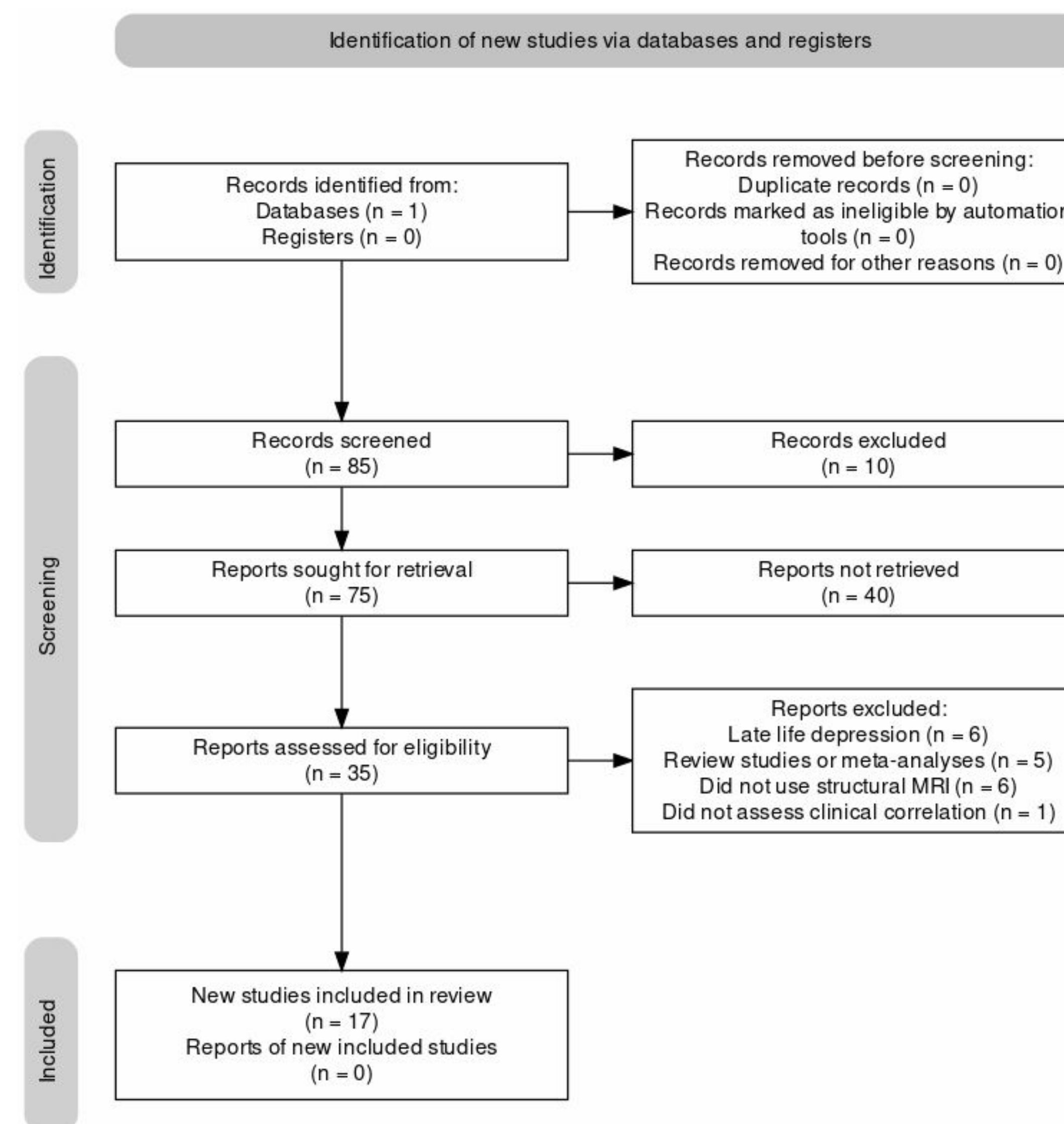


Fig 1. PRISMA Flow Diagram³ depicting identification, screening and final inclusion of articles in this study.

From the remaining 17 articles, the following information was extracted:

- 1) First author, publication year
- 2) Sample size (including breakdown of treatment vs. control and gender when provided)
- 3) Changes to hippocampal gray matter (GM) volume
- 4) Changes in clinical measures of depression severity.

Note: This study may be limited by the fact that it only included papers written in English, potentially excluding relevant papers in other languages.

Results

All articles (n = 17) revealed an increase in hippocampal GMV in patients with MDD following ECT.

Some articles saw bilateral hippocampal GMV changes post-ECT, while others revealed alterations in unilateral hippocampal and even hippocampal subregion volume. These hippocampal subregions included the dentate gyrus, the CA4 subfield, and the hippocampal-amygdaloid transition region (HATA).

There were mixed results regarding the association between hippocampal GMV increases and MDD clinical outcomes.

8 papers found a significant correlation, 6 papers did not find a significant correlation, and 3 papers found both significant and non-significant correlations or found both positive and negative significant associations within the hippocampus.

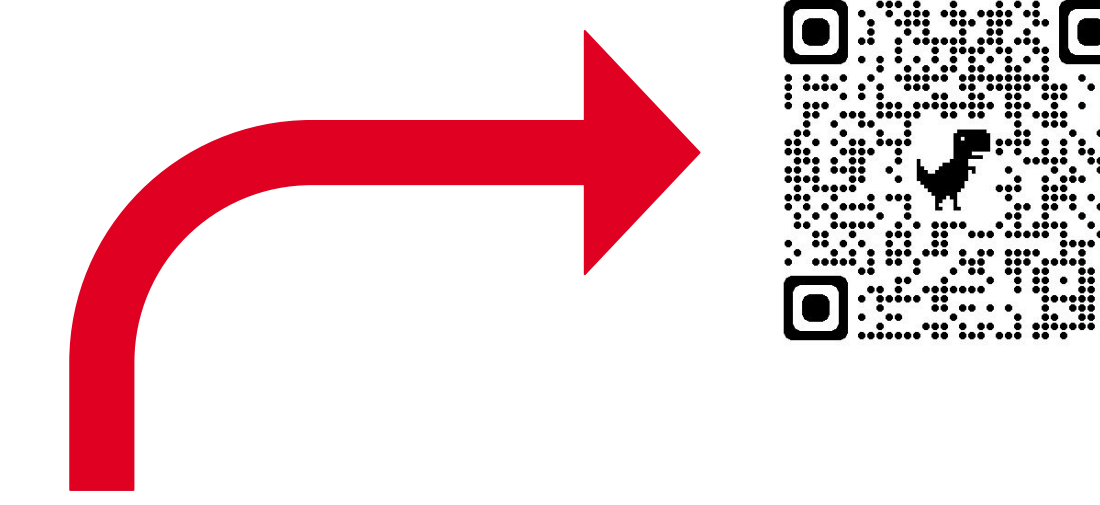


Table 1. Authorship, year of publication, sample size, volumetric changes (measured with structural MRI) in the hippocampus after ECT and associations between structural hippocampal changes and clinical outcomes for n = 17 studies (2013 to 2023).

First Author, Year of publication	Sample Size	Hippocampal Volumetric Changes Post-ECT	Correlation Between Hippocampal Changes and Clinical Outcomes
T. Bracht et al. 2023	n = 20 (16 MDD, 4 depressed BPD)	Hippocampal volumes increased in the ECT group but not in healthy controls.	Positive correlation between increased right posterior hippocampus and symptom reduction in HAM-D-21 scores, but other correlations did not yield significant results.
J. Van der A et al. 2023	n = 23	In MDD patients, both left and right hippocampal volumes increased.	Following ECT, increased volume of left hippocampus and in left and right hippocampal subfields correlated with decreased verbal memory function.
J. Xu et al. 2022	n = 23 (dataset 1), n = 41 (dataset 2)	In MDD patients, bilateral hippocampal GMV increased in both datasets.	No significant correlation was found between baseline hippocampal volumes and change in HAM-D scores.
L. Gyger et al. 2021	n = 9	In MDD patients, GMV along the hippocampal longitudinal axis increased, predominantly at its anterior portion.	There was no difference in reduction of depression severity (HAM-D) between ECT and no-ECT groups at any time point. Larger anterior hippocampal volumes at baseline were correlated with better clinical outcome post-ECT. However, larger hippocampal volume changes post-ECT were associated with less clinical improvement.
K. Ciel et al. 2020	n = 22	In MDD patients, volume significantly increased in the right and left dentate gyri. There were also increases in 15 out of 20 secondary hippocampal ROIs.	Clinical improvement in depression as measured by HAM-D was correlated with increase in right dentate gyrus volume and increase in volume of other hippocampal subregions.
O. Ousdal et al. 2020	n = 423 (228 MDD, 95 HC)	In MDD patients, there were volumetric increases in 79 out of 84 gray matter regions of interest, including the bilateral hippocampus (p < 0.001).	Following ECT, MADRS scores decreased significantly (p < 0.001). However, increases in specific anatomic brain volumes may not be a feasible biomarker of clinical response since the structural changes following ECT in depression are broadly distributed. The association between number of ECTs and changes in MADRS did not depend on the method of electrode placement.
G. Gryglewski et al. 2019	n = 14 (10F, 3M)	Following (right unilateral) ECT in MDD patients, right hippocampal volume increased (139.4 mm, SD = 34.9). Subcortical volume increases were localized to the HATA and the granule cell and molecular layer in the dentate gyrus.	Lower pre-ECT volumes were correlated with increased symptom improvement for the following hippocampal subregions: right presubiculum, left presubiculum, and right subiculum body and head. Larger pre-ECT volumes correlated with increased symptom improvement for the following hippocampal subregions: left subiculum head and right parasubiculum.
A. Takamiya et al. 2019	n = 45 (25 MDD, 20 HC)	In MDD patients, volume increased in CA4/DG (hippocampal subfields).	Clinically remitted patients post-ECT had larger volume increases in the right CA4/DG than non-remitted patients. Increases in the CA4/DG volumes returned back to baseline levels after 3 months, regardless of clinical state. Post-ECT volumetric changes were associated with clinical remission (HAM-D) and age.
B. Cao et al. 2018	n = 39 (24 MDD [14F, 10M], 15 HC [10F, 5M])	Following ECT in MDD patients, hippocampal subfield volumes increased (CA2/3, CA4, GCL, ML, subiculum) (p < 0.05).	Following ECT in MDD patients, HAM-D scores were reduced significantly (p < 0.001). Using machine learning, the clinical outcomes post-ECT could be predicted using hippocampal subfield volumes, but not whole hippocampal volumes.
L. Ollendick et al. 2018	n = 376 (281 MDD, 95 HC)	In MDD patients, hippocampal linear volume increased by 0.28% per ECT session (p < 0.001). Electrode placement impacted left, but not right, hippocampal enlargement.	ECT-related volume increases were associated with poorer MADRS outcomes (p = 0.005), but after controlling for ECT number, volume change is not associated with clinical outcome (p = 0.069). Therefore, hippocampal enlargement may not be a useful biomarker for treatment outcome.
M. Ciano et al. 2017	n = 22 (12 TRD [6F, 6M], 10 HC [5F, 5M])	In TRD patients, there were significant GMV increases in several regions, including the hippocampus and parahippocampal cortex.	Multiple regression analysis revealed significant (p = 0.047) positive association between clinical improvement in depressive symptoms and GM volume increase in the left MTL (which includes the hippocampus).
S. Joshi et al. 2016	n = 75 (43 MDD [23F, 20M], 32 HC [18F, 14M])	In MDD patients, hippocampal volumes increased (p < 0.001).	Related to hippocampal volume increases post-ECT, depressive symptoms improved (p < 0.01). Patients with smaller baseline hippocampal volumes were more likely to show volume increases and improved clinical response following ECT.
R. Redlich et al. 2016	n = 45 (24 MDD, 21 HC)	Following ECT in MDD patients, there were bilateral hippocampal volume increases. Meanwhile, the medication only patients did not demonstrate these structural changes.	Hippocampal plasticity was not correlated with clinical response, which indicates that the GM volume increases may be a result of the underlying mechanism of ECT, and not the driver. Univariate whole-brain regression analysis demonstrated that the pre-treatment GM volume of the subgenual cingulate gyrus was positively associated with clinical response to ECT.
R. Wolf et al. 2016	n = 33 (12 MDD, 21 HC)	In MDD patients, there was a significant increase in MTL structural network strength (includes hippocampus and parahippocampal cortex).	The increase in MTL structural network strength was not associated with clinical improvement in MDD.
M. Ota et al. 2015	n = 15	In MDD patients, there were significant increases in GMV in the MTL.	The increase in MTL GMV were correlated with clinical improvement as measured by HAM-D scores.
J. Dukart et al. 2014	n = 31 (15 unipolar & 5 bipolar depression [6F, 4M], 21 HC [13F, 8M])	Unipolar and bipolar depression responded differently to ECT and produced varied local volume changes. The hippocampal complex demonstrated a significant increase in GMV at 3 months post-ECT.	ANCOVA (P < 0.05) identified significant interactions between ECT, unipolar/bipolar depression diagnosis and both subgenual cortex (p = 0.005) and hippocampal cortex (p = 0.026). This ANCOVA explained 76.5% of variance in clinical measures of symptomatic improvement.
I. Tendolkar et al. 2013	n = 15	In TRD patients, there were significant GMV increases in the hippocampus (p < 0.005) with no evidence for change in global brain volume.	It is unclear whether this change in volume is related to treatment effects.

Abbreviations: major depressive disorder (MDD), treatment-resistant depression (TRD), healthy controls (HC), female (F), male (M), medial temporal lobe (MTL), electroconvulsive therapy (ECT)

Conclusion

Using updated literature, this systematic review **confirmed** the results of prior reviews and meta-analyses, which found that ECT in patients with MDD is associated with significant **increases in hippocampal GMV**.

Meanwhile, our findings were **inconclusive** regarding whether increased hippocampal GMV mediates the improved **clinical outcomes** for MDD post-ECT.

Importantly, this review highlighted **knowledge gaps** for further investigation...

- Heterogeneity of the hippocampus → volumetric changes were varied depending on if the study focused on bilateral hippocampal, unilateral hippocampal, or hippocampal subregion GMV
- Most findings suggested that hippocampal CMV increase was a biomarker of ECT-induced symptomatic improvement
 - However, one paper (Ousdal 2020) found broadly distributed structural changes post-ECT that were not specific to the hippocampus
- Inconsistent reporting of time and dose-dependence of ECT effects

Next Steps

- Include multiple hippocampus breakdowns (bilateral, unilateral, sub-hippocampal)
- Do not investigate the hippocampus in isolation, also compare to changes whole brain GMV and connected specific regions (e.g. subgenual cortex)
- Record dose and time dependence of ECT effects
- Meta-analysis across multiple imaging modalities (sMRI, fMRI, MRS, DTI)

Resources

- Bains N, Abdjiddid S. Major Depressive Disorder. *PubMed*. Published April 10, 2022. <https://www.ncbi.nlm.nih.gov/books/NBK55907/>
- Li M, Yao X, Sun L, et al. Effects of Electroconvulsive Therapy on Depression and Its Potential Mechanism. *Frontiers in Psychology*. 2020;11(80). doi:<https://doi.org/10.3389/fpsyg.2020.00080>
- Njau S, Joshi SH, Espinoza R, et al. Neurochemical correlates of rapid treatment response to electroconvulsive therapy in patients with major depression. *Journal of psychiatry & neuroscience: JPN*. 2017;42(1):6-16. doi:<https://doi.org/10.1503/jpn.150177>
- Wilkinson ST, Sanacora G, Bloch MH. Hippocampal Volume Changes Following Electroconvulsive Therapy: A Systematic Review and Meta-analysis. *Biological Psychiatry: Cognitive Neuroscience and Neuroimaging*. 2017;2(4):327-335. doi:<https://doi.org/10.1016/j.bpsc.2017.01.011>
- (PRISMA) Haddaway, N. R., Page, M. J., Pritchard, C. C., & McGuinness, L. A. (2022). PRISMA2020: An R package and Shiny app for producing PRISMA 2020-compliant flow diagrams, with interactivity for optimised digital transparency and Open Synthesis Campbell Systematic Reviews, 16, e1230. <https://doi.org/10.1002/ci2.1230>